



Histological and Immunohistochemical Study of Cardio Protective Effect of Sildenafil against Isoproterenol Induced Cardiotoxicity in Male Rats

Ahmed M. Mahmood^{1*}, Mustafa Ghazi Al-Abbasi², Mustafa Mohammed Al-Obeidy³, Ban Jumaa Qasim⁴, Nawfal Am.Numan⁵, Fatima Ali Tawfiq⁶

1.* Department of Pharmacology and toxicology, Al-Mustansiriyah university, M.Sc. program, Bagdad, Iraq.

2. Department of Pharmacology and Toxicology, College of Pharmacy, Al-Mustansiriyah University, Bagdad, Iraq.

3. Department of Human Anatomy, Histology and Embryology, College of Medicine, Al- Mustansiriyah University, Bagdad, Iraq.

4. Department of Histopathology, College of Medicine, Al-Nahrain University, Bagdad, Iraq.

5. Department of Pharmacology and Toxicology, College of Pharmacy, Al-Ahilyya Amman University, Amman, Jordan.

6. department of pharmaceutical, College of Pharmacy, Al-Ahilyya Amman University, Amman, Jordan.

Received: 30-10-2016; Revised: 02-01-2017; Accepted: 15-01-2017.

ABSTRACT

The objective of the study is to investigate cardio protective effect of sildenafil against isoproterenol induce cardio toxicity by using histological and immune histochemical methods. Thirty six adult male Wistar rats (weighing 200–250 gm) were divided into 3 groups randomly each group contains 12 animals, group A which received oral saline as –ve control by using oral gavage tube for 21 days group B received normal saline for 21days while group C received sildenafil citrate (10 mg/kg/day) oral solution by using oral gavage tube for 21 days. Both group B and group C received isoproterenol (150 mg/kg) subcutaneously at day 20th and 21st consecutively, after 24 hours, from the last dose of Isoproterenol. It was find that animals treated with isoproterenol showed a significant increase histological changes and degree of stain up take of immune histochemical markers (TNF-alfa&IL-1beta) compared with control group, while, sildenafil pretreated group showed highly decrease in histological changes and degree of stain up take of immune histochemical markers (TNF-alfa&IL-1beta) compared with isoproterenol group. This study shows that sildenafil citrate has a potential cardio protective effect through: Sildenafil citrate decreases the percentage of histopathological changes of myocardial tissue; Current studies demonstrate that sildenafil citrate exerts its anti-inflammatory characteristic by reducing the percentage of stain uptake of tumor necrosis factor –alfa & interleukin 1beta.

Keywords: sildenafil, Histological, immune histochemical, TNF-alfa, IL-1beta.

INTRODUCTION

Cardiovascular aging

Vascular aging, a basis factor for cardiovascular disease and health status in the elderly.¹ Two main mechanisms of age-related cardiovascular disease: oxidative stress and inflammation.

Oxidative stress

Additional reactive oxygen species (ROS) and superoxide anion produced by oxidative stress and low-grade inflammation associated aging recapitulate age-related cardiovascular dysfunction, that is, left ventricular hypertrophy, fibrosis, and diastolic dysfunction in the heart in addition endothelial dysfunction, reduced vascular elasticity, and amplified vascular stiffness¹ Oxidative stress is a well-established mark of cardiovascular disease and there is strong evidence for a pivotal role of reactive oxygen and nitrogen species (RONS)². Presently, oxidative stress and diminished antioxidant defence mechanisms are thought to be crucial contributors to the cardiovascular aging process³ Oxidative stress develops as an importance of excessive generation of reactive oxygen species (ROS), by enzymes such as nicotinamide adenine dinucleotide phosphate NADPH oxidase, uncoupled nitric oxide synthase, and xanthine oxidase, by the mitochondrial electron transport chain, and as a consequence of reduced antioxidant capacity⁴. In the senescent heart, the majority of ROS are

derived from NADPH oxidase and the mitochondrial electron transport chain (ETC).⁵ Enlarged oxidative stress and ROS production, associated with decreased endothelial NO bioavailability, have been noticed during the aging process in different vascular beds in various animal models including the rat aorta⁶ coronary arteries⁷ and mouse aorta⁸.

Inflammation

Inflammation arises in the vasculature as a response to injury, lipid peroxidation, and perhaps infection. Numerous risk factors, including hypertension, diabetes, and smoking, are augmented by the harmful effects of oxidized low-density lipoprotein cholesterol, initiating a chronic inflammatory reaction, the outcome of which is a vulnerable plaque, prone to rupture and thrombosis.⁹ These pathophysiological facts provide latent targets for measurement as a means to identify and monitor the ongoing inflammatory process. Possible targets for measurement include proinflammatory risk factors such as oxidized low-density lipoproteins, proinflammatory cytokines (eg, interleukin-1, tumor necrosis factor- α), adhesion molecules (eg, intercellular adhesion molecule-1, selectins), inflammatory stimuli with hepatic properties (eg, interleukin-6) or the products of the hepatic stimulation, such as SAA, C-reactive protein (CRP), and a host of additional acute-phase reactant¹⁰. The inorganic free radical, NO, is a crucial mediator in a wide series of biological processes, including regulation of inflammation.



During the inflammatory response, activated inflammatory cells produce reactive oxygen and nitrogen species, including NO; the capability of NO to control apoptosis of a range of cells, as well as the inflammatory cells themselves. Depending on local concentrations and the cell type, NO can demonstrate both pro-apoptotic and anti-apoptotic properties¹¹. Inhibitors of PDE (PDEIs) can prolong the intracellular action of cAMP and cGMP¹², therefore, cGMP accumulation may inhibit inflammation, and as such it is a latent tool against the evolution of diseases in which inflammation plays a vital role.¹³ Chronic treatment with sildenafil, a PDE5 inhibitor (PDE5i), is related to cardio protection and reduced levels of circulating inflammatory cytokines. A greatly promising role for PDE5i in the modulation of inflammatory processes has also been reported in ischemia-reperfusion injury in the heart¹⁴.

Interleukin -1 beta

IL-1 comprises of two distinctive ligands (IL-1 α and IL-1 β) with high order homology and indistinguishable biological activities¹⁵ that signal through the IL-1 type I receptor (IL-1RI). A naturally occurring IL-1 receptor antagonist (IL-1Ra) binds to IL-1RI without originating signal transduction and stops IL-1 signaling, competitively inhibiting IL-1-mediated responses. Developing evidence proposes that the balance between IL-1 agonists and antagonists plays a critical role in a variety of cardiovascular conditions. IL-1 may play a role in atherothrombotic disease by stimulating formation of atheromatous lesions, augmenting vascular inflammation, and triggering plaque destabilization. Following myocardial infarction, IL-1 critically normalises the inflammatory response and is involved in the development of antagonistic remodeling by improving expression of matrix metalloproteinases. IL-1 signaling may also be an important mediator in the pathogenesis of heart failure by defeating cardiac contractility, promoting myocardial hypertrophy and prompting cardiomyocyte apoptosis¹⁶ IL-1 is steadily induced and activated following tissue injury and seems to play an essential role in many inflammatory conditions¹⁷.

Tumor necrosis factor-alpha

It is a fundamental cytokine involved in inflammation, immunity, cellular homeostasis and tumour development¹⁸. Increased circulating levels of TNF- α were detected in heart failure patients from diverse aetiologies. It is possible that the basic mechanism of upregulation of TNF- α production is secondary to progressive heart failure. Evidence for a direct heart damaging role of TNF- α supports the notion that increased TNF- α production may play a major role in the pathogenesis of advanced heart failure¹⁹. TNF- α is convoluted to reduced expression of endothelial nitric oxide synthases (eNOS) and as a result impaired nitric oxide (NO) production leading to endothelial dysfunction²⁰. In fact, incubation of endothelial cells with serum from patients with congestive heart failure was

presented to down regulate eNOS expression in a TNF- α dependent fashion.²¹

MATERIALS AND METHODS

Animals and study design

Thirty six adult male Wistar rats (weighing 200–250 gm) were used in the experiment after getting approval from ethical committee in collage of pharmacy/Al-Mustansiriyah University. Animals were divided into 3 groups randomly each group contains 12 animals, **group A** which received oral saline as –ve control by using oral gavage tube for 21 days **group B** received normal saline for 21days while **group C** received sildenafil citrate (10 mg/kg/day) oral solution by using oral gavage tube for 21 days. Both **group B** and **group C** received isoproterenol (150 mg/kg) subcutaneously at day 20th and 21st consecutively, after 24 hours, from the last dose of Isoproterenol.

Plastic cages of (20x25x35 cm) dimension used to keep three animals per cage. Animals within the same cage were differentiated by tail markings using a waterproof marker. Before starting study protocol the animals were kept for 2 weeks under controlled conditions of temperature of (22 \pm 1^oC) with light schedule of 12-12 hour's light/dark cycles and the animal house was provided with an air vacuum to be adapted with the environment of the animal house. Foods commercial pellets and water were accessible freely to the animals.

Treatment administration

Each day of the experiment sildenafil citrate oral stock solution (3.5mg/ml) is prepared freshly by dissolving (50mg) white to off-white sildenafil citrate crystalline powder in 14.3 ml distilled water. A calculated dose of sildenafil for each rat (in treatment group) was drawn in an insulin syringe then delivered to the animal via direct instillation into the stomach or lower esophagus(gavage) of a conscious rat is by far the most accurate method to administer drugs into the gastrointestinal tract. Using adequate manual restraint, the rat was held in a vertical position with its nose aimed toward the ceiling so as to form a straight line between the rat's mouth and stomach. Next, the gavage needle was gently inserted into the oral cavity through the left diastema and passed along the roof of the oral cavity toward the ramus of the right mandible. As the animal swallows, the instrument was advanced down into the esophagus. Finally, once the needle was advanced to the appropriate depth, the solution slowly infused by depressing the plunger of the syringe.

Animal sacrifice

At the end of 22 days, blood collected from animals by cardiac puncture then rats euthanized by decapitation.²²

Organ harvest

After opening the abdomino thoracic cavity the heart was easily identified, and transferred to the fixative after



washing with normal saline after carefully cutting thoracic bone.²³

Tissue preparation

After fixation with 10% buffered formalin tissue processing will be started according to Bancroft and Stevens the tissues were processed as follows²⁴. Fixation, dehydration, clearing, impregnation, embedding, sectioning, using semi-enclosed Benchtop tissue processor Leica TP1020, heated paraffin embedding module Leica EG1150 H, cold Plate for modular tissue embedding system Leica EG1150 C, after programing according to type of staining.

Tissue staining

Hematoxylin and eosin staining

A- Staining

Loading slides in (Leica Multistainer ST5020) after programing as follow²⁴:

- Harri'shematoxylin solution 3 minutes.
- Running tap water until for 5 minutes.
- Acid alcohol 5 seconds.
- Running tap water 1minute.
- Eosin 1% solution for 30 seconds.
- Running tap water for 5 minutes.
- Dehydrated in graded alcohol (70%, 80%, 90% and 99%) 1minute for each, until dry, thin cleared in xylene (2-3 minutes).

Dislodging slides from Leica multi stainer and mounted by DPX mounting medium.

B- Microscopically study

A digital microscope system with Leica DM4000 B LED was used to capture five zones of a slide (corners and the center) which randomly at X40 magnification were selected.

Immuno histochemistry staining

A biotin free-horseradish peroxidase conjugate, 3-3'diaminobenzidine HRP/DAB system is intended for use with primary antibody from rabbit or mouse for the qualitative identification of antigens by light microscopy and immune histochemistry in formalin fixed and paraffin embedded tissues. After application of primary antibody which bind to specific antigens present in the specimen, any excess antibody is removed by washing, followed by sequential incubation with a horseradish peroxidase conjugate to the primary anti body and unbound enzyme is removed by washing. Staining is completed and the brown end product is formed after incubation with the substrate-chromogen (3-3'diaminobenzidine) (DAB) and it is oxidized when it donates electrons to activate the HRP/H₂O₂ reaction²⁴.

Assessment of histological analysis of the heart tissue

- A digital microscope system with Leica DM4000 B LED was used to capture five zones of a slide which randomly at X 20, X40 magnification were selected.

- The myocardial damage was determined by scoring method depending on the severity as follows:

No change=0 score

Mild=1 score (focal myocytes damage or small multifocal degeneration with slight degree of inflammation)
Moderate=2 score (extensive myofibrillar degeneration)
Marked=3 score (Necrosis with diffuse inflammation)^(25,26)

- An immune histochemical based scoring system was utilized for analyses of TNF-alfa and IL-1beta as strength of stain uptake be cells (intensity of staining) per field in a blind fashion and the scores calculated as following:

Score 1 = weak staining

Score 2= moderate staining

Score 3= strong staining^(27,28)

Effect of isoproterenol and sildenafil on histological Changes

At sacrifice, microscopic findings of control rat heart showed a normal myofibrillar structure with striations, branched appearance and continuity with adjacent myofibrils (Figures 1- A, B) occurs mainly in zero score. ISO-induced rats revealed marked myofibrillar degeneration with infiltration of neutrophil granulocytes and interstitial edema (Figures 1-C, D) the characterizations of score 3. The tissue sections from treatment groups sildenafil+ISO (Figures 1-E, F), showed some infiltration with neutrophil granulocytes, interstitial edema and some discontinuity with adjacent myofibrils but the morphology of cardiac muscle fibers was relatively well preserved with no evidence of focal necrosis when compared with ISO-induced group, which is the main features of score 1.

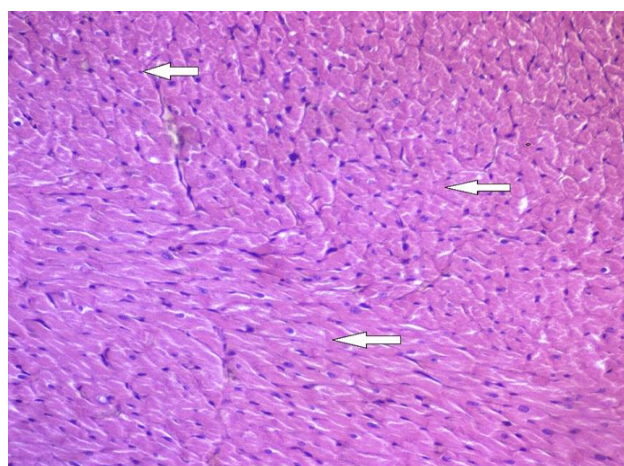


Figure (3-5): Light microscopic section of rat cardiac tissue of H&E stain of control group (A) which received oral saline for 21 days showing normal myocardial muscle fiber, no myocyte damage or inflammation.(20X).

The percentages in figure (2) showed that the score in control group was 100% in score zero while isoproterenol group expressed a high percentage 79% score 3 & 21% score 2. The sildenafil pretreated group showed the

highest percentage in score 1 66.67% & low percentage in score 2 33.33%.

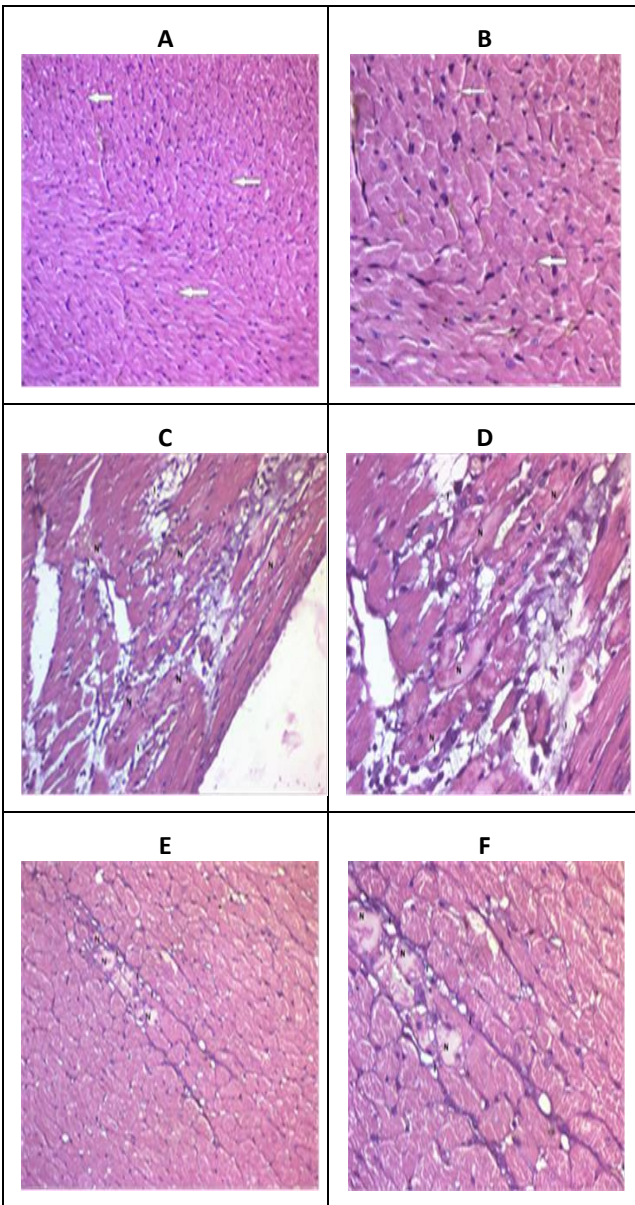


Figure 1: (A&B)Light microscopic section of rat cardiac tissue of H&E stain of control group (A) which received oral saline for 21 days showing normal myocardial muscle fiber, no myocyte damage or inflammation (20X ,40X respectively). **(C &D)**Light microscopic section of rat cardiac tissue of H&E stain of group (B) which received isoproterenol (150mg/kg) S.C. for two consecutive days showing diffuse myocyte necrosis with inflammation (20X, 40X respectively). **(E & F)**Light microscopic section of rat cardiac tissue of H&E stain of group

(c) which received sildenafil (10 mg/kg/day) for 21 days in addition to ISO administered S.C. at day 20 &21 from starting sildenafil showing focal myocyte damage with slight degree of inflammation (20X , 40X respectively). (N necrosis, I inflammation).

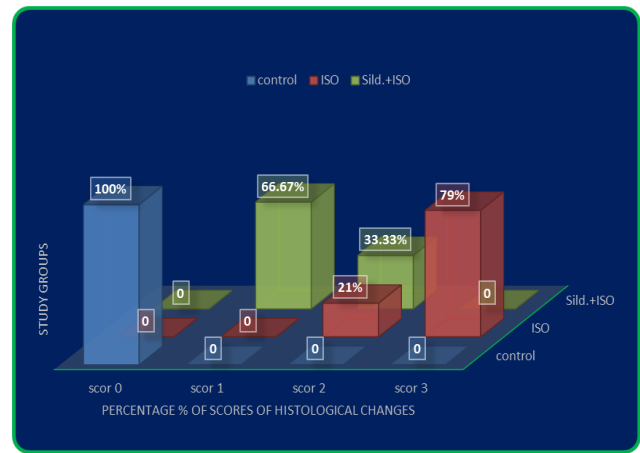


Figure (2): Percentage of histological changes scoring among study groups

Changes in immune histochemistry of inflammatory markers

Immuno histochemical based scoring system was utilized for analyses of TNF-alfa and IL-1beta as strength of stain up take, and the scores calculated as following and expressed as percentages:

- Score 1 = weak staining
- Score 2= moderate staining
- Score 3= strong staining

Tumor necrosis factor-alfa

The percentage of stain uptake in the figure (4) showed: weak up take of stain in control group as shown in the figure (3-A) which represent 100% score 1 while isoproterenol group was strongly uptake of stain as shown in the figure (3-B) expressing extremely high percentage 83.33% in score 3 & low percentage 16.67% in score 2. The sildenafil pretreated group showed the highly percentage 75% in score 2 and low percentage 25% in score 3 of stain uptake as shown in the figure (3-C).

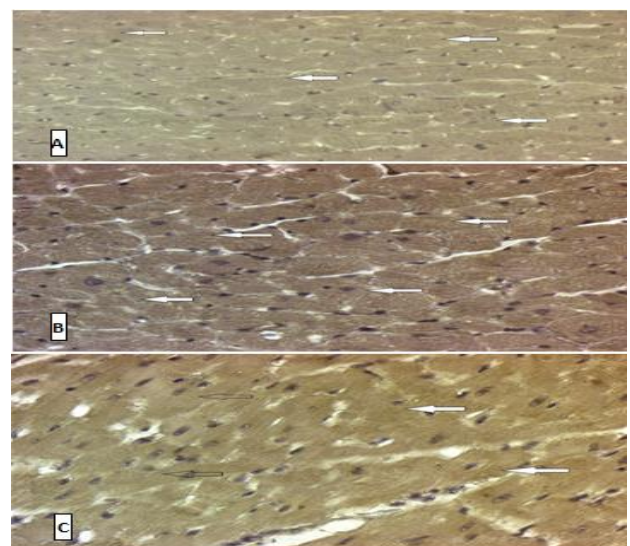


Figure 3:(A) Microphotograph of Immuno histochemical (IHC) staining of rat cardiac tissue of control group (a) of TNF-alfa showing +ve brown cytoplasmic immune

histochemical stain of weak intensity, (40x). **(B)** Microphotograph of Immuno histochemical (IHC) staining of rat cardiac tissue of group (b) which received isoproterenol (150mg/kg) SC for two consecutive days of TNF-alfa showing +ve brown cytoplasmic immune histochemical stain of strong intensity, (40x). **(C)** Microphotograph of immune histochemical (IHC) staining of rat cardiac tissue of group(c) which received sildenafil (10mg/kg/day) for 21 days in addition to ISO administered S.C. at day 20 & 21 from starting sildenafil of TNF-alfa showing +ve brown cytoplasmic immune histochemical stain of moderate intensity.(40x).

histochemical stain of weak intensity. (40x). **(B)** Microphotograph of immune histochemical (IHC) staining of rat cardiac tissue of group (b) which received isoproterenol (150mg/kg) S.C. for two consecutive days of IL-1Beta showing +ve brown cytoplasmic immune histochemical stain of strong intensity. (40x). **(C)** Microphotograph of immune histochemical (IHC) staining of rat cardiac tissue of group (c) which received sildenafil (10 mg/kg/day) for 21 days in addition to ISO administered S.C. at day 20 & 21 from starting sildenafil of IL-1Beta showing +ve brown cytoplasmic immune histochemical stain of moderate intensity. (40x).

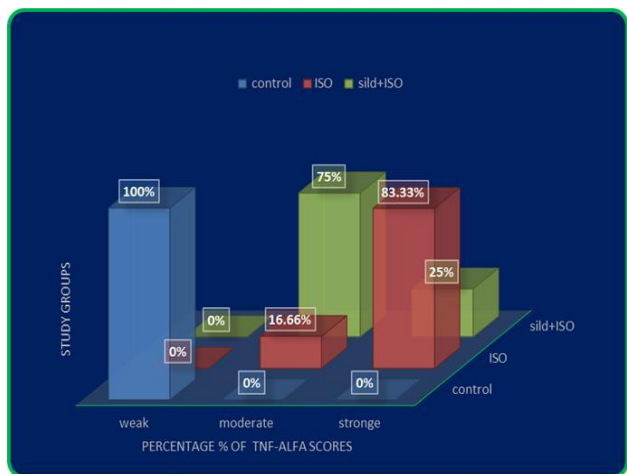

Figure (4): Percentage of TNF-alfa stain uptake scoring among study groups

Interliukine-1beta

The percentage of stain up take in the figure (6) showed: weak up take of stain in control group as shown in the figure (5-A) which represent 100% score 1 while isoproterenol group was strongly uptake of stain as shown in the figure (5-B) expressing extremely high percentage 83.33% in score 3 & low percentage 16.67% in score 2.

The sildenafil pretreated group showed the highly percentage 75% in score 2 and low percentage 25% in score 3 of stain up take as shown in the figure (5-C).

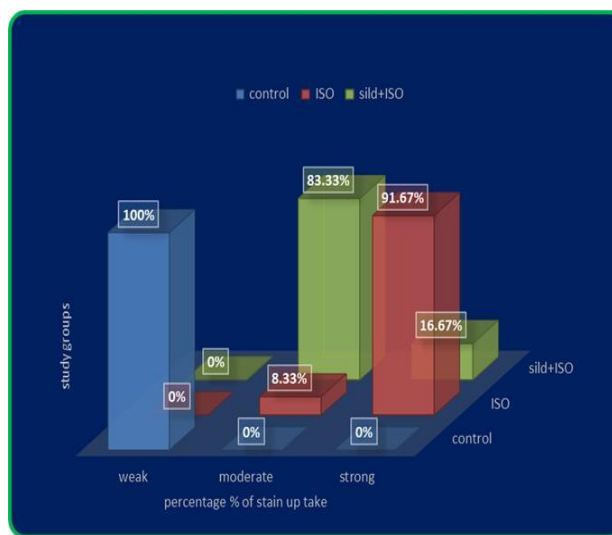


Figure (6): percentage of IL-1beta stain uptake scoring among study groups

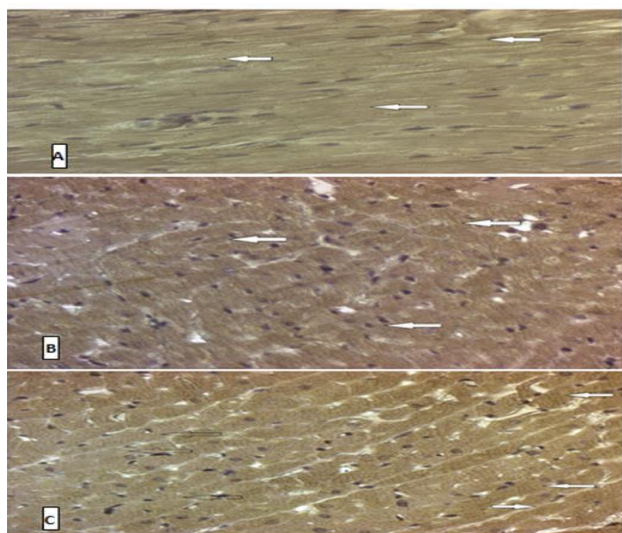


Figure (5): (A) Microphotograph of immune histochemical (IHC) staining of rat cardiac tissue of control group (a) of IL-1Beta showing +ve brown cytoplasmic immune

Histopathological modifications in myocardium:

In this study control group show no histopathological changes (normal appearance myocardial muscle fiber) no myocyte damage or inflammation. While, in isoproterenol treated group diffused myocyte necrosis with marked inflammation. ISO in high doses induces morphological and functional variations in the heart leading to subendocardial myocardial ischemia, hypoxia, necrosis, and finally fibroblastic hyperplasia with decreased myocardial compliance and inhibition of diastolic and systolic function, which nearly resembles local myocardial infarction-like pathological changes seen in human myocardial infarction²⁹. These findings are in line with Malcolm *et. Al.*³⁰ In sildenafil pretreated group it found that focal myocyte damage with slide degree of inflammation lower than that of isoproterenol treated group, this finding totally agree with previous studies.^{31,32}

Changes in tumour necrosis factor – alfa

Expression of various cytokines especially that of TNF-α is improved in various patho physiological states associated with increased oxidative stress, which in turn helps the induction of various other cytotoxic substances on

endothelial cells and myocytes. This has intense pathological significance, in terms of development of cardio myopathy, myocyte apoptosis, transmural myocarditis and biventricular fibrosis as well as overall functional deterioration of heart³³. In this study, the percentage of inflammatory markers up-regulated during ischemic episode induced by isoproterenol, while they were down regulated in sildenafil pre-treated groups, validating their protective effect, which is in line with previous studies^{33,34}. The increase circulating TNF-alpha stimulates intracellular adhesion molecule-1 (ICAM-1) expression on cardiac myocyte, which in turn promotes adhesive interaction between transmigrated neutrophils and cardiac myocytes of the reperfused myocardium. The end result is the release of harmful substances, such as oxygen free radicals, leukotrienes and cytokines from these neutrophils³⁵ for all mentioned above the immune histopathological marked decrease in percentage of staining intensity of pretreated group is approved this concept.

Change in interleukin – 1beta

Interleukin-1 (IL-1) acts a role in mediating acute inflammation during ischemia-reperfusion (I/R) injury in the heart, which leads to both necrosis and apoptosis of cardio myocytes.³⁶ Two linked genes code for 2 different proteins (IL-1 α and IL-1 β) that bind the same receptor (type I). IL-1 β , the essential form of circulating IL-1, is primarily synthesized as a precursor (proIL-1 β) that becomes activated by caspase-1 cleavage in the setting of a macromolecular structure known as the in flamma some.³⁷ In the present study, sildenafil treatment suppressed the severity of acute MI and reduced the percentage of IL-1 β -positive myocardial cells compared with which observed immune histochemistry. Accordingly, the beneficial effects of sildenafil may be partly due to the suppression of inflammatory cytokines in which these findings are agree with other previous studies.^{38,39}

REFERENCES

1. Wu J, Xia S, Kalionis B, Wan W, Sun T, Wu J, et al. The Role of Oxidative Stress and Inflammation in Cardiovascular Aging, the Role of Oxidative Stress and Inflammation in Cardiovascular Aging. *BioMed Res Int Bio Med Res Int*. 2014 Jul 20, 2014, e615312.
2. Schulz E, Wenzel P, Münzel T, Daiber A. Mitochondrial redox signaling: Interaction of mitochondrial reactive oxygen species with other sources of oxidative stress. *Antioxid Redox Signal*. 20(2), 2014 Jan 10, 308–24.
3. Bachschmid MM, Schildknecht S, Matsui R, Zee R, Haeussler D, Cohen RA, et al. Vascular aging: chronic oxidative stress and impairment of redox signaling-consequences for vascular homeostasis and disease. *Ann Med*. 45(1), 2013 Feb, 17–36.
4. Rassaf T, Bryan NS, Maloney RE, Specian V, Kelm M, Kalyanaraman B, et al. NO adducts in mammalian red blood cells: too much or too little? *Nat Med*. 9(5), 2003 May, 481–2, author reply 482–3.
5. Boudina S. Cardiac Aging and Insulin Resistance: Could Insulin/Insulin-Like Growth Factor (IGF) Signaling be used as a Therapeutic Target? *Curr Pharm Des*. 19(32), 2013, 5684–94.
6. Márمول F, Sánchez J, López D, Martínez N, Roselló-Catafau J, Mitjavila MT, et al. Loss of adaptation to oxidative stress as a mechanism for aortic damage in aging rats. *J Physiol Biochem*. 63(3), 2007 Sep, 239–47.
7. Csiszar A, Ungvari Z, Koller A, Edwards JG, Kaley G. Aging-induced proinflammatory shift in cytokine expression profile in coronary arteries. *FASEB J Off Publ Fed Am Soc Exp Biol*. 2003 Jun;17(9):1183–5.
8. Francia P, Gatti C delli, Bachschmid M, Martin-Padura I, Savoia C, Migliaccio E, et al. Deletion of p66shc Gene Protects Against Age-Related Endothelial Dysfunction. *Circulation*. 110(18), 2004 Nov 2, 2889–95.
9. Willerson JT, Ridker PM. Inflammation as a Cardiovascular Risk Factor. *Circulation*. 109(21 suppl 1), 2004 Jun 1, II – 2 – II – 10.
10. Pearson TA, Mensah GA, Alexander RW, Anderson JL, Cannon RO, Criqui M, et al. Markers of Inflammation and Cardiovascular Disease Application to Clinical and Public Health Practice: A Statement for Healthcare Professionals from the Centers for Disease Control and Prevention and the American Heart Association. *Circulation*. 107(3), 2003 Jan 28, 499–511.
11. Maskrey BH, Megson IL, Whitfield PD, Rossi AG. Mechanisms of Resolution of Inflammation A Focus on Cardiovascular Disease. *Arterioscler Thromb Vasc Biol*. 31(5), 2011 May 1, 1001–6.
12. Peixoto CA, Gomes FO dos S. The role of phosphodiesterase-inhibitors in prostatic inflammation: a review. *J Inflamm Lond Engl [Internet]*. 2015 Sep 15 [cited 2016 Apr 6], 12. Available from: www.ncbi.nlm.nih.gov/pmc/articles/PMC4570643/.
13. Zhao S, Zhang L, Lian G, Wang X, Zhang H, Yao X, et al. Sildenafil attenuates LPS-induced pro-inflammatory responses through down-regulation of intracellular ROS-related MAPK/NF- κ B signaling pathways in N9 microglia. *Int Immunopharmacol*. 11(4), 2011 Apr, 468–74.
14. Venneri MA, Giannetta E, Panio G, De Gaetano R, Gianfrilli D, Pofi R, et al. Chronic Inhibition of PDE5 Limits Pro-Inflammatory Monocyte-Macrophage Polarization in Streptozotocin-Induced Diabetic Mice. *PLoS ONE [Internet]*. 2015 May 11 [cited 2016 Apr 6]; 10(5). Available from: <http://www.ncbi.nlm.nih.gov/pmc/articles/PMC4427327/>
15. Allan SM, Tyrrell PJ, Rothwell NJ. Interleukin-1 and neuronal injury. *Nat Rev Immunol*. 5(8), 2005 Aug, 629–40.
16. Bujak M, Frangogiannis NG. The role of Interleukin-1 in the pathogenesis of heart disease. *Arch Immunol Ther Exp (Warsz)*. 57(3), 2009, 165–76.
17. Dinarello CA. The role of the interleukin-1-receptor antagonist in blocking inflammation mediated by interleukin-1. *N Engl J Med*. 343(10), 2000 Sep 7, 732–4.
18. Balkwill F. Tumour necrosis factor and cancer. *Nat Rev Cancer*. 9(5), 2009 May, 361–71.
19. Ferreira RC, Ianni BM, Abel LC, Buck P, Mady C, Kalil J, et al. Increased plasma levels of tumor necrosis factor-alpha in



- asymptomatic/"indeterminate" and Chagas disease cardiomyopathy patients. *Mem Inst Oswaldo Cruz.* 98(3), 2003 Apr, 407–12.
20. Asifa GZ, Liaquat A, Murtaza I, Kazmi SAR, Javed Q, Asifa GZ, et al. Tumor Necrosis Factor-Alpha Gene Promoter Region Polymorphism and the Risk of Coronary Heart Disease, Tumor Necrosis Factor-Alpha Gene Promoter Region Polymorphism and the Risk of Coronary Heart Disease. *Sci World J Sci World J.* 2013 Dec 5, 2013, 2013, e203492.
 21. Goodwin BL, Pendleton LC, Levy MM, Solomonson LP, Eichler DC. Tumor necrosis factor- α reduces argininosuccinate synthase expression and nitric oxide production in aortic endothelial cells. *Am J Physiol - Heart Circ Physiol.* 293(2), 2007 Aug 1, H1115–21.
 22. Parasuraman S, Raveendran R, Kesavan R. Blood sample collection in small laboratory animals. *J Pharmacol Pharmacother.* 1(2), 2010, 87–93.
 23. Species Specific Information: Rat [Internet]. [Cited 2016 Jun 22]. Available from: <http://web.jhu.edu/animalcare/procedures/rat.html>
 24. Bancroft JD, Gamble M. *Theory and Practice of Histological Techniques.* Elsevier Health Sciences; 2008. 742 p.
 25. Manodeep Chakraborty & Syed Mohammed Basheeruddin A, Department of Pharmacology, Krupanidhi College of P, 560 035, India. Interaction of *Semecarpus anacardium* L. with propranolol against isoproterenol induced myocardial damage in rats. 2010;
 26. Naz F, Jahan N, Sultana N. Protective Effect of Peanut (*Arachis hypogaea* L.) and Its Combination with Propranolol in Cardiotoxic Rats. *J Bangladesh Soc Physiol* [Internet]. 2015 Mar 30 [cited 2016 Jul 7];9(1). Available from: <http://www.banglajol.info/index.php/JBSP/article/view/22792>
 27. Charafe-Jauffret E, Tarpin C, Bardou V-J, Bertucci F, Ginestier C, Braud A-C, et al. Immunophenotypic analysis of inflammatory breast cancers: identification of an "inflammatory signature." *J Pathol.* 202(3), 2004 Mar, 265–73.
 28. Maryla Krajewska. *Image Analysis Algorithms for Immunohistochemical Assessment of Cell Death Events and Fibrosis in Tissue Sections.* 2009.
 29. Li H, Xie Y-H, Yang Q, Wang S-W, Zhang B-L, Wang J-B, et al. Cardioprotective Effect of Paeonol and Danshensu Combination on Isoproterenol-Induced Myocardial Injury in Rats. *PLOS ONE.* 7(11), 2012 Nov 6, e48872.
 30. York M, Scudamore C, Brady S, Chen C, Wilson S, Curtis M, et al. Characterization of Troponin Responses in Isoproterenol-Induced Cardiac Injury in the Hanover Wistar Rat. *Toxicol Pathol.* 35(4), 2007 Jun 1, 606–17.
 31. Zhang Q, Xiang J, Wang X, Liu H, Hu B, Feng M, et al. β 2-adrenoceptor agonist clenbuterol reduces infarct size and myocardial apoptosis after myocardial ischaemia/reperfusion in anaesthetized rats. *Br J Pharmacol.* 160(6), 2010 Jul, 1561–72.
 32. Haleagrahara N, Varkkey J, Chakravarthi S. Cardioprotective Effects of Glycyrrhizic Acid Against Isoproterenol-Induced Myocardial Ischemia in Rats. *Int J Mol Sci.* 12(10), 2011 Oct 21, 7100–13.
 33. Mukherjee S, Banerjee SK, Maulik M, Dinda AK, Talwar KK, Maulik SK. Protection against acute adriamycin-induced cardiotoxicity by garlic: Role of endogenous antioxidants and inhibition of TNF- α expression. *BMC Pharmacol.* 20, 2003 Dec, 3, 16.
 34. Shukla SK, Sharma SB, Singh UR, Ahmad S, Maheshwari A, Misro M, et al. *Eugenia jambolana* Pretreatment Prevents Isoproterenol-Induced Myocardial Damage in Rats: Evidence from Biochemical, Molecular, and Histopathological Studies. *J Med Food.* 17(2), 2014 Feb 1, 244–53.
 35. Gurevitch J, Frolkis I, Yuhas Y, Lifschitz-Mercer B, Berger E, Paz Y, et al. Anti-Tumor Necrosis Factor-Alpha Improves Myocardial Recovery After Ischemia and Reperfusion. *J Am Coll Cardiol.* 30(6), 1997 Nov 15, 1554–61.
 36. Suzuki K, Murtuza B, Smolenski RT, Sammut IA, Suzuki N, Kaneda Y, et al. Overexpression of Interleukin-1 Receptor Antagonist Provides Cardioprotection Against Ischemia-Reperfusion Injury Associated With Reduction in Apoptosis. *Circulation.* 2001 Sep 18, 104 (suppl 1), I – 308 – I – 313.
 37. Dinarello CA. Interleukin-1 in the pathogenesis and treatment of inflammatory diseases. *Blood.* 117(14), 2011 Apr 7, 3720–32.
 38. Okabe T, Kishimoto C, Hattori M, Nimata M, Shioji K, Kita T. Cardioprotective effects of 3-methyl-1-phenyl-2-pyrazolin-5-one (MCI-186), a novel free radical scavenger, on acute autoimmune myocarditis in rats. *Exp Clin Cardiol.* 9(3), 2004, 177–80.
 39. El-Shitany NA, El-Desoky K, El-Shitany NA, El-Desoky K. Protective Effects of Carvedilol and Vitamin C against Azithromycin-Induced Cardiotoxicity in Rats via Decreasing ROS, IL1- β , and TNF- α ; Production and Inhibiting NF- κ B and Caspase-3 Expression, Protective Effects of Carvedilol and Vitamin C against Azithromycin-Induced Cardiotoxicity in Rats via Decreasing ROS, IL1- β , and TNF- α ; Production and Inhibiting NF- κ B and Caspase-3 Expression. *Oxidative Med Cell Longev Oxidative Med Cell Longev.* 5, 2016 May 2016, 2016, e1874762.

Source of Support: Nil, Conflict of Interest: None.

